13th Batch

Exam Committee

NEU 241 Midterm

Neu Midterm 55/60 questions

1- A patient presents to the ER with apparent flaccid paralysis. It was noted that he consumed canned beans earlier in the day. After investigation, it was revealed the patient ingested botulinum toxin. What is the mechanism behind botulism that lead to this presentation?
   A- Inhibit release of the neurotransmitter from inhibitory cells
   B- Inhibit release of neurotransmitters from motor neurons
   C- Destroy presynaptic calcium channels
   D- Destroy post-synaptic nicotinic ACh receptors

   Ans: B

2- A new drug that reduces CSF production is used as a treatment for hydrocephalus. It works by acting on the apical surface of the choroidal vessel on which active transporter?
   A- Na+/K+ ATPase
   B- Na+/2Cl-/K+
   C- HCO3-/Cl-
   D- K+ channels

   Ans: A

3- The patella is struck with a with a reflex hammer. This reflex is elicited through which of the following receptors?
   A- Golgi tendon organ
   B- Nociceptors
   C- Muscle spindle
   D- Pancianian corpuscle

   Ans: C

4- The accommodation reflex is through?
   A- Inferior colliculus
   B- Ciliary ganglion
   C- Superior colliculus
   D- Superior salivatory nucleus

Ans: B

5- A 60-year-old man presents to the emergency room with slurred speech and right-sided facial drooping. He was diagnosed with acute ischemic stroke. It was noted that he also had signs of Horner's syndrome. Lesion to which of the following tracts is responsible for Horner syndrome?
   A- Hypothalamospinal
   B- Vestibulospinal
   C- Rubrospinal
   D- Corticobulbar
   E- Spinotectal

Ans: A

6- Which nuclei/ ganglia is responsible for the innervation of the parotid gland?
   A- Inferior salvatory
   B- Superior salvatory
   C- Edinger-Westphal
   D- Ciliary ganglion
   E- Nucleus Tractus Solitarius

Ans: B

7- Which of the following neurotransmitters is transported through EAATS?
   A- Glycine
   B- GABA
   C- Serotonin
   D- Histamine
   E- Glutamate

Ans: A

8- During weightlifting, multiple receptors are activated. One of which are the Golgi tendon organs. Golgi tendon organ works by:
   A- Activating alpha motor neurons on the muscle doing the action and inhibiting alpha motor neurons for the antagonist muscle
   B- Activating the alpha motor neurons on the antagonist muscle and inhibiting the lower motor neurons for the muscle doing the action
   C- Activating the alpha motor neurons of the muscles doing the action and inhibiting the alpha motor neurons of muscles in the opposite limb
   D- Activating gamma motor neurons to increase sensitivity of the muscle to stretch and activating the alpha motor neurons for the muscle doing the action.

Ans: B

9- Which of the following neurofibromatosis syndromes has the potential to become malignant?
   A- Schwannomas
   B- Café-Au-Lait spots
   C- Cutaneous neurofibroma
   D- Plexiform neurofibroma

Ans: D

10- Ali is a right-handed 40-year-old man that had difficult speaking. When asked to raise the LEFT hand, he would raise the RIGHT hand. He had trouble counting despite being an accountant and could not name his fingers. Where is the lesion located?
   A- Left temporal lobe
   B- Right temporal lobe
   C- Right parietal lobe
   D- Left parietal lobe
   E- Right Occipital lobe

ANS- D

11- Which of these neurotransmitters binds to ionotropic receptors only?
   A- Glycine
   B- Glutamate

C- Epinephrine
D- GABA
E- Serotonin

Ans: A

12- Which of the following is the correct order for the synthesis of catecholamines?
A- Tyrosine—dopa—dopamine—epinephrine—norepinephrine
B- Tyrosine—dopa—epinephrine—dopamine—norepinephrine
C- Tyrosine—dopa—dopamine—norepinephrine—epinephrine
D- Tyrosine—dopamine—dopa—norepinephrine—epinephrine

Ans: C

13- A 6-month-old infant is suffering from epilepsy. Further investigation revealed a congenital vitamin B6 deficiency. Impaired synthesis of which neurotransmitter would be expected?
A- Glutamate
B- GABA
C- Glycine
D- Nitric oxide
E- Epinephrine

Ans: B

14- The membrane potential of a neuron is -60mV. The equilibrium potential of Cl- is -50mV. If the conductance of Cl- is increased, what would be expected happen the membrane potential?
A- Hyperpolarization due to Cl- influx
B- Depolarization due to Cl- influx
C- Depolarization due to Cl- efflux
D- Hyperpolarization due to Cl- efflux

Ans: C

15- At which point in the following graph would the Na+ inactivation gate close?

A- 1
B- 2
C- 3
D- 4
E- 5

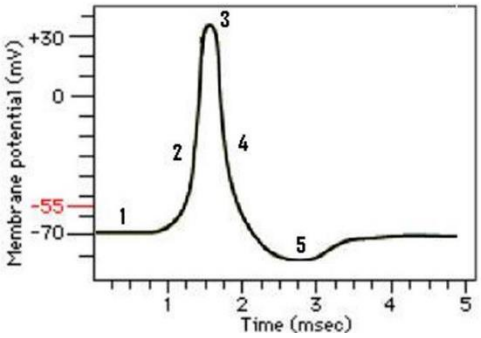

Ans: C

16- A 60-year-old woman suffers from acute-onset hemiparesis, ptosis, lateral strabismus (eyes going laterally). Which of the following vessels is involved? *(Note this question had an unlabeled diagram with arrows pointing at the vessels listed in the choices bellow, but I couldn't find any image that resembles the one we had)*

A- PCA
B- MCA
C- ACA
D- PICA
E- Anterior Spinal

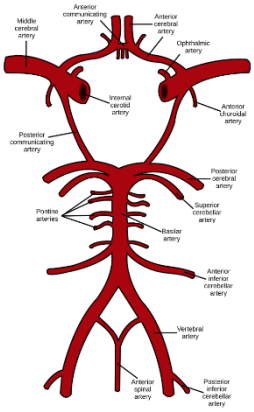

Ans: A

17- A defect in the fusion of the vesicle to release the neurotransmitter was observed in neurons. Which of the following could be the defective protein?

A- SNAP-25
B- Synapsin
C- Synaptotagmin
D- Synaptobrevin

Ans: C

18- Organophosphates work by?

A- Inhibiting ACh degradation

B- Binding to ACh receptors irreversibly
C- Stimulating ACh degradation
D- Preventing the release of ACh

Ans: A

19- GTPase activating proteins work on which of the following molecules?
A- Heterodimeric G protein
B- RAS
C- MAP kinase
D- Akt kinase

Ans: A

20- A 40-year-old patient presents to the emergency room with severe headache, bradycardia, irregular breathing, and elevated blood pressure. Imaging reveals an enlarged 3rd and lateral ventricles but normal-sized 4th ventricle. The site of obstruction is most likely in which of the following structures?
A- Formina of Luschka
B- Formina of Monro
C- 4th ventricle
D- Central canal
E- Aqueduct of sylvus

Ans: E

21- Slow-adapting receptors for fine touch and pressure?
A- Meissner's corpuscles
B- Nociceptors
C- Pancianian corpuscles
D- Ruffinian corpuscles
E- Merkel discs

Ans: E

22- A man stepped on a nail with his barefoot, after which he immediately lifted the foot off the ground. Based on this reflex, which of the following sets of receptors would you expect to be activated?
A- Muscle spindle-Golgi tendon organs
B- Golgi tendon-nociceptors
C- Nociceptors-muscle spindle
D- Nociceptors-mechanoreceptors

Ans: C

23- Modulation of pain is controlled by which center?
A- Periaqueductal grey matter
B- Interneurons
C- Raphe nucleus
D- Ventral medulla

Ans: A

24- A 60-year-old woman presents to the physician with right-sided weakness. A test was performed where a rod was slid across the medial aspect of her foot which caused her big toe to extend upwards. Based on these findings, What else would you expect to find?
A- Fasciculation
B- Spasticity
C- Hyporeflexia
D- Atrophy of muscles

Ans: B

25- At what level do you perform a lumbar puncture in adults?
A- L3-4
B- L5-S1
C- S1-S2

D- L2-3
E- L1-L2

Ans: A

26- In which of the following neuropathies would you find evidence central chromatolysis?
A- In axonal dystrophy
B- In Wallerian degeneration
C- In axonal dystrophy and Wallerian degeneration
D- In demyelination
E- In demyelination and Wallerian degeneration

Ans: C

27- The most common acute demyelinating polyneuropathy is?
A- GBS
B- Multiple sclerosis
C- Diabetic neuropathy
D- ALS

Ans: A

28- The most common cause of diffuse axonal injury is:
A- Cerebral edema
B- Acceleration-deceleration injuries
C- Stroke
D- Blunt trauma
E- Tumors

Ans: B

29- A patient was suspected of having a CNS tumor. After collecting samples, you observe a tumor staining positive for GFAP with marked nuclear atypia and necrosis under light microscopy. The grade of this tumor is?

A- Grade 4
B- Grade 1
C- Grade 2
D- Grade 3

Ans: D

30- You examine a tumor under light microscopy. You notice that it is hemorrhagic and has a an area of necrosis with a serpentine-like shape with a pseudo-palisading pattern. The tumor most likely seen is?

A- Glioblastoma multiforme
B- Medulloblastoma
C- Pilocytic astrocytoma
D- Meningioma
E- Ependymoma

Ans: A

31- A slide of a CNS tumor is shown on the right. What is the diagnosis?

A- Hemangioblastoma
B- Ependymoma
C- Glioblastoma multiforme
D- Schwannoma
E- Medulloblastoma

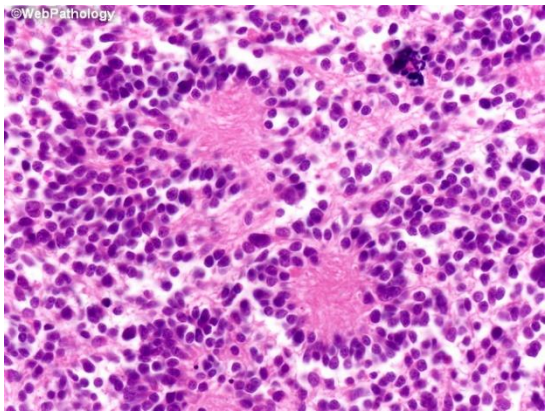

Ans: E

32- Choose the picture that shows meningioma:

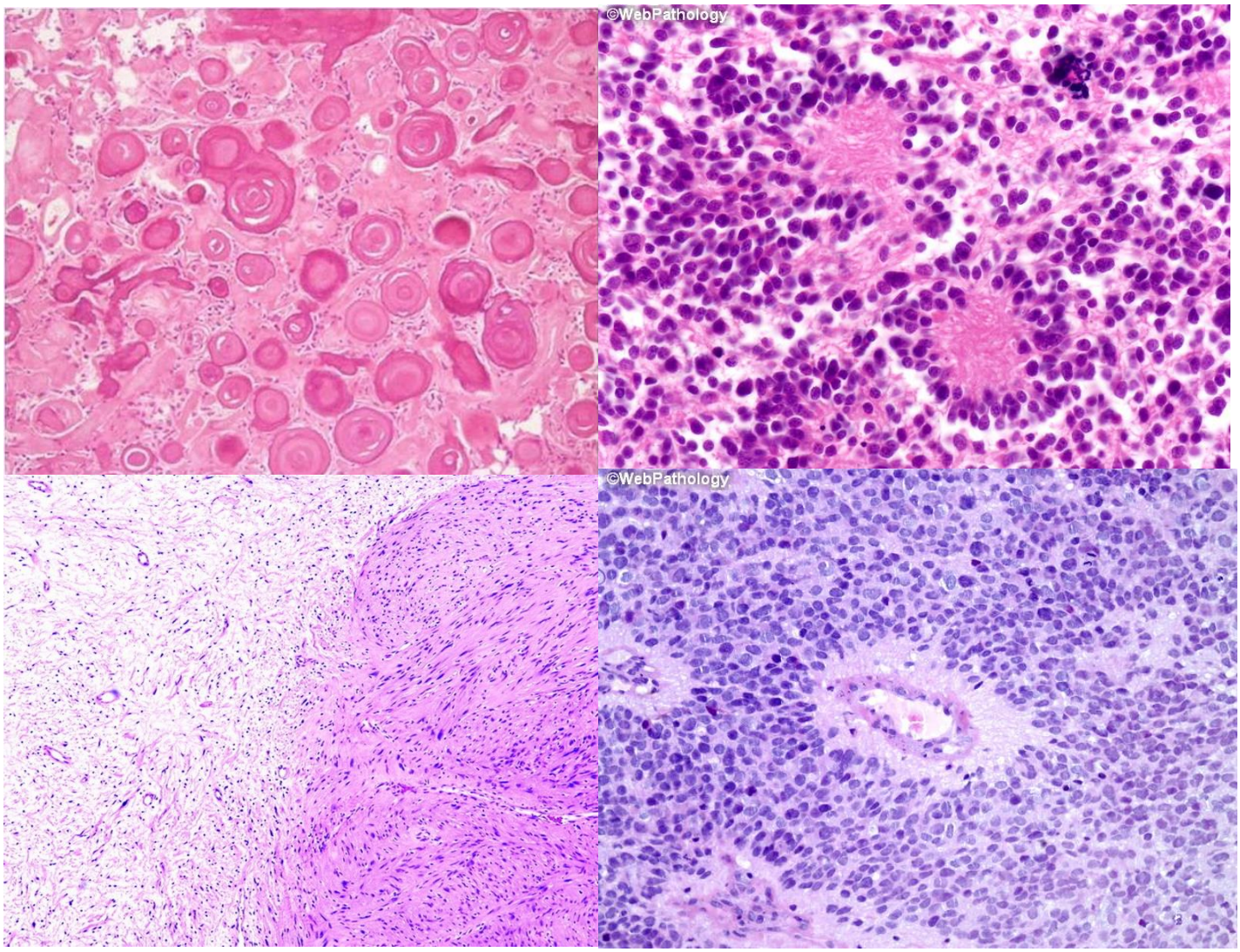

Ans: Top left picture (for reference: top right is medulloblastoma; bottom left is schwannoma; bottom right is ependymoma)

33- A 40-year-old man is having difficulty speaking and swallowing. Damage to which of the following nuclei is responsible for this presentation?

A- Nucleus ambiguous
B- Nucleus Solitarius
C- Nucleus Gracilis
D- Facial nucleus
E- Trigeminal Motor nucleus

Ans: A

34- A man received multiple stab wounds on the back at the level of T12. Imaging revealed hemi-section of the spinal cord. It was noted that he had left lower limb spastic paralysis. Where would the sense of vibration be still intact?

A- Right lower limb
B- Left lower limb
C- Both limbs
D- None of the limbs

Ans: A

35- Patient developed right sided ptosis and lateral strabismus after a stroke. He also had left sided spastic paralysis. MRI would show a stroke involving which part of the brain?
A- Left crus cerebri
B- Right crus cerebri
C- Basis of the pons
D- Right medullary pyramid
E- Dorsal midbrain

Ans: B

36- A 30-year old woman suffered from a spinal injury while undergoing a surgery for aortic dissection. Examination revealed that she has spastic paralysis bilaterally and loss of pain and temp bilaterally. What is the likely diagnosis?
A- Syringomyelia
B- Central cord syndrome
C- Brown-Sequard syndrome
D- Spinal muscular atrophy
E- Anterior cord syndrome

Ans: E

37- A 40-year-old man was rushed to the emergency room after a severe car accident. Examination revealed loss of pain and temperature bilaterally in the upper limb and bilateral motor paresis with 'sacral sparing'. What is the diagnosis?
A- Central cord syndrome
B- Syringomyelia
C- Anterior cord syndrome
D- Posterior cord syndrome

E- Complete resection of the spine

Ans: A

38- The tract responsible for vibration and two-touch discrimination decussates at the level of?
A- Pons
B- Spinal cord
C- Midbrain
D- Medulla
E- Thalamus

Ans: D

39- What happens when protein kinase C activates CREB?
A- Opening of Ca++ channels
B- Phosphorylation of proteins leading to their activation or inhibition
C- Translation occurs
D- Transcription begins

Ans: D

40- A man that will undergo surgery soon had experienced malignant hyperthermia in a previous surgery before. Which anesthetic would you recommend this time?
A- Propofol
B- Sevoflurane
C- Nitrous oxide
D- Isoflurane

Ans: A

41- Woman that will undergo surgery soon had experienced severe vomiting in a previous surgery before. She says she doesn't want that this time. What would you recommend this time?
A- Propofol
B- Etomidate
C- Ketamine
D- Thiopental
E- Midazolam

Ans: A

42- A woman had suffered from recurrent migraines for the past 6-7 months, each lasting hours. What drug would you give to prevent future migraine attacks?
A- Sumatriptan
B- Ergotamine
C- Amitriptyline
D- Paracetamol
E- Diclofenac

Ans: C

43- Which of the following drugs would you use to treat addiction in heroin addicts?
A- Tramadol
B- Codeine
C- Meperidine
D- Morphine
E- Methadone

Ans: E

44- A 50-year-old woman presents to the emergency room unconscious. She has marked respiratory depression and pinpoint pupils. A relative of hers confirms that she has history of heroin abuse. The drug of choice for treatment in this case would be?
A- Methadone
B- Pentazocine

C- Morphine
D- Naloxone

Ans: D

45- Which of the following drugs is contraindicated in pregnant women to treat migraines?
A- Sumatriptan
B- Ergotamine
C- NSAIDs
D- Paracetamol

Ans: B

46- A 50-year-old man presents to the physician's office after losing face sensations. Which nuclei are affected in this case?
A- Trigeminal nuclei
B- Nuclei ambiguous
C- Facial nuclei
D- Nuclei of Tractus Solitarius

Ans: A

47- Visceral special sensations are conveyed to which of the following nuclei?
A- Spinal trigeminal nuclei
B- Primary sensory trigeminal nuclei
C- Vestibular and cochlear nuclei
D- Nuclei solitarius

Ans: D

48- A 50-year-old woman presents to the physician's office after her sense of taste. Examination reveals that the taste sensation is lost in the entire tongue. Where is the lesion most likely located?

A- Rostral medulla
B- Caudal midbrain
C- Rostral pons
D- Rostral midbrain
E- Caudal medulla

Ans: A

49- A 50-year-old man presented to the ER following a stroke. Examination revealed medial strabismus of the left eye, right sided hemiparesis, and loss of taste sensation in the anterior 2/3 of the left tongue. Which of the following is the diagnosis?

A- Lateral medullary syndrome
B- Medial medullary syndrome
C- Lateral pontine syndrome
D- Weber syndrome
E- Ventrocaudal pontine syndrome

Ans: E

50- A man had a lesion in the occipital lobe. Which of the following deficits would you expect to find?

A- Loss of sensation and spastic paralysis in the lower limbs
B- Bilateral hemianopia
C- Loss of sensation and spastic paralysis in the upper limbs
D- Loss of hearing unilaterally
E- Hemineglect of the left side

Ans: B

51- The transmission of first pain is through which fibers?

A- A-beta fibers
B- C fibers

C- A-delta fibers
D- A-alpha fibers

Ans: C

52- A patient is brought to a neurological clinic by his wife because he was only shaving the left side of his face and shampooing the left side of his head. Where could the lesion be?
A- Left parietal lobe
B- Right parietal lobe
C- Left occipital lobe
D- Right temporal lobe
E- Left frontal lobe

Ans: A

53- Man comes in with difficulty to speak however he is fluent. He has trouble repeating words. He was very frustrated with because of his inability to form words and was able to comprehend the commands of the examiner. Where is the problem?
A- Wernicke's area
B- Broca's area
C- Temporal lobe
D- Superior longitudinal fasciculus

Ans: D

54- A 40-year-old man is brought to the ER following a stroke. After the patient was stabilized, it was noted that he had difficulty speaking and swallowing. Further examination revealed of the sensations of pain and temperature on the right side of his body. He also complained of vertigo. The stroke affected which of the following arteries?
A- PCA
B- AICA
C- PICA
D- ACA
E- MCA

Ans: C

55- A 50-year-old hypertensive woman complains of numbness and weakness in her leg and foot. Occlusion of which of the following vessels may account for this complaint?

A- Anterior cerebral artery
B- Posterior cerebral artery
C- Middle cerebral artery
D- Posterior inferior cerebellar artery
E- Basilar artery

Ans: A

The 13th batch wishes you the best in your upcoming exam <3. May the odds ever be in your favor.